

CASE REPORT

Correction of Chest Wall Deformity After Implant-Based Breast Reconstruction Using poly-L-Lactic Acid (Sculptra)

Matthew R. Schulman, MD, Justin Lipper, BA, and Richard A. Skolnik, MD

Division of Plastic and Reconstructive Surgery, The Mount Sinai School of Medicine and The Mount Sinai Hospital, New York, New York

■ **Abstract:** Implant-based breast reconstruction after mastectomy offers excellent cosmetic results in select individuals. However, this technique may result in a step-off between the implant and the soft tissue of the chest wall, which can be problematic in the extremely thin patient. Also, the removal of soft tissue can result in prominent ribs and visible intercostal spaces. A number of surgical options exist to correct these defects and include dermal grafts, flap reconstruction, and implant exchange. We present the case of a thin woman with a persistent “step-off” deformity and visible intercostal spaces after mastectomy and two-stage implant reconstruction. Placement of acellular cadaveric dermis (AlloDerm) failed to improve the appearance of her chest wall. The authors utilized poly-L-lactic acid (Sculptra) for soft tissue augmentation of her chest wall with significant esthetic improvement. This novel use of poly-L-lactic acid offers a useful alternative to invasive surgical procedures to correct a soft tissue deformity of the chest wall. While poly-L-lactic acid has recently gained popularity for soft tissue augmentation of the face, to date, no reports in the literature exist describing its use in the correction of difficult chest wall defects after mastectomy and implant reconstruction. We maintain that poly-L-lactic acid may also be useful to improve a variety of soft tissue deformities of the breast. ■

Key Words: breast deformity, breast reconstruction, chest wall deformity, poly-L-lactic acid, Sculptra

Fundamental to breast reconstruction after mastectomy is the choice between implant reconstruction and autologous tissue transfer. A thin body habitus makes breast reconstruction challenging because reconstructive options may be limited by a lack of donor tissue. Problems associated with implant reconstruction are well reported and can include malposition, extrusion, infection, and hardware failure. In very thin patients, the lack of soft tissue covering the implant may also increase the incidence of rippling and implant visibility and palpability (1). They may also complain of a visible “step-off” deformity superiorly, as well as prominent ribs and visible intercostal spaces. The use of acellular cadaveric dermis (AlloDerm; Life Cell Corporation, Branchburg, NJ) has been described to correct some of these implant-related problems (2). Although this option does exist, the degree to which the graft will offer sustained correction of the deformity may be variable. It also

requires an invasive procedure to place the graft. As the number of women choosing implant reconstruction approaches 35,000 per year, postoperative chest wall deformities in thin patients will become a more frequent complaint.

We present a case of a thin woman who complained of a superior “step-off” deformity and visible intercostal spaces after implant reconstruction; the placement of acellular cadaveric dermis failed to correct the soft tissue deformity. We chose to use injectable poly-L-lactic acid (Sculptra; Dermik Laboratories, Berwyn, PA) to correct the persistent chest wall deformity. The U.S. Food and Drug Administration has approved Sculptra as the first injectable facial volumizer in the treatment of HIV-associated lipoatrophy. Sculptra has also been described for off-label uses in areas of the body such as the hands and neck, décolleté and atrophic scars, and congenital, traumatic, and postsurgical depressions (3).

This use of Sculptra for the treatment of a chest wall deformity after implant-based breast reconstruction was successful after AlloDerm failed to adequately correct the deformity. We offer this previously undescribed use of Sculptra for treatment of

Address correspondence and reprint requests to: Matthew R. Schulman, MD, 21 E. 87th St., Suite 1A, New York, NY 10128, USA, or e-mail: matthewschulman.md@gmail.com.

© 2007 Blackwell Publishing, Inc., 1075-122X/07
The Breast Journal, Volume 14 Number 1, 2008 90–94

recalcitrant soft tissue defects after breast implant reconstruction. This nonsurgical technique can be used to primarily correct a similar soft tissue deformity, and can be adapted address other soft tissue defects throughout the body.

PATIENT HISTORY AND RESULTS

A 63-year-old woman who stands 5'6" tall and weighs 113 pounds underwent an immediate first stage breast reconstruction with submuscular McGhan (McGhan Medical, Santa Barbara, CA) tissue expander style #133MV after right simple mastectomy. Six months later, she underwent exchange of the tissue expander (250 mL) to a permanent saline implant (McGhan style 363LF; 165 mL). The patient subsequently complained about a visible step-off along the superior aspect of this implant as well as prominent ribs and visible intercostal spaces (Fig. 1). The implant was soft without signs of capsular contracture. Surgical correction was attempted with the placement of extra thick AlloDerm within the superior aspect of her chest wall as well as in the area of the visible intercostal spaces. There was initial improvement in the chest wall contour during the early postoperative period. However, these results were temporary and the soft tissue defect recurred within 6 months.

Sculptra was injected into the subcutaneous tissue and deep dermal layers of the superior and medial right chest wall. Treatment was directed to the supe-

rior step-off between the chest wall and implant, as well as her visible intercostal spaces. A total of four treatments at 1 month intervals were performed. Each treatment consisted of two vials (367.5 mg each) of Sculptra diluted with 1.5 mL of 1% lidocaine and 4 mL of sterile water via a macrodroplet technique (Fig. 2). Significant esthetic improvement was reported by the patient who now wears clothing that she was unable to wear prior to correction of the deformity (Fig. 3). The results have been withstanding 9 months after the final treatment. She suffered no complications during the treatment and reports no palpable or visible nodules.

DISCUSSION

There are many potential problems specific to thin patients undergoing breast reconstruction. One of the most common complications from a lack of subcutaneous tissue is a visible implant, especially at the superior breast pole. This visible step-off can be present despite the use of anatomic-shaped implants. The lack of soft tissue can also result in prominent ribs and visible intercostal spaces. Correcting implant-related problems in extremely thin individuals is challenging. Although silicone may reduce visibility of the implants, this is not always successful in preventing the superior "step-off" or visible intercostal spaces. Autologous tissue is an excellent option for primary reconstruction, but donor sites may be limited in thin

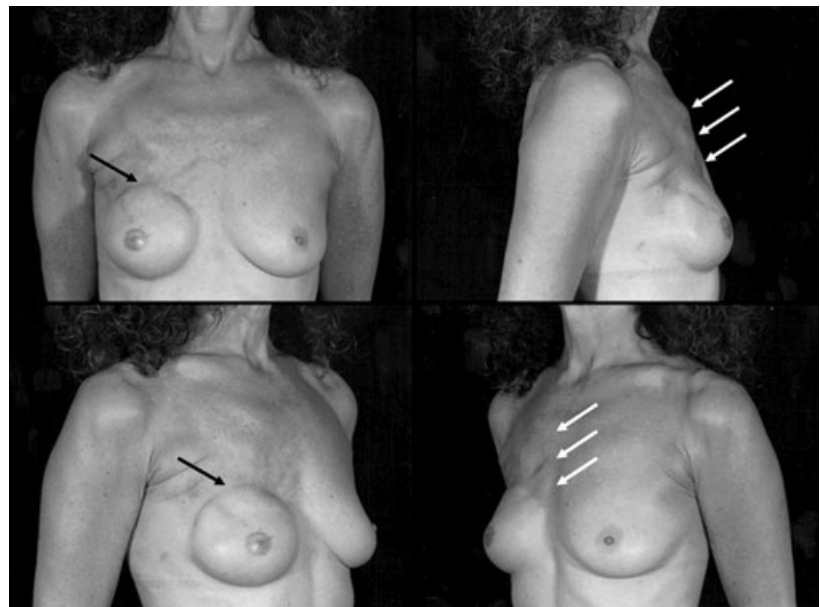


Figure 1. Persistent chest wall deformity after two-stage implant reconstruction and attempted repair with acellular cadaveric dermis (AlloDerm). Note the superior pole "step-off" (black arrow) and the prominent ribs with visible intercostals spaces (white arrows).

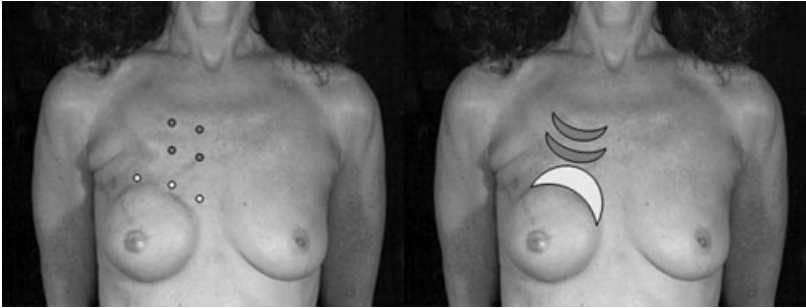


Figure 2. Poly-l-lactic acid (Sculptra) injection technique. The sites of injection are shown on the left-hand side, and the corresponding areas of contour correction are shown on the right-hand side.

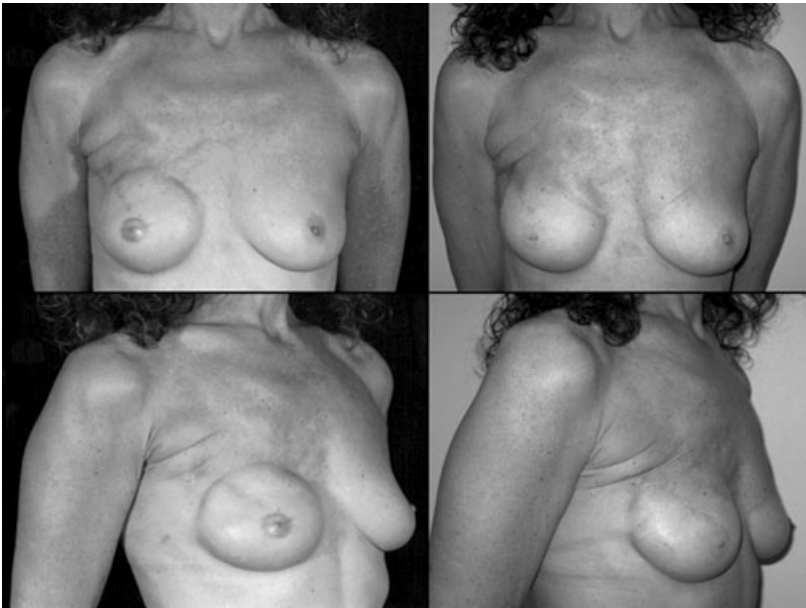


Figure 3. Improved chest wall contour 9 months after completion of treatment consisting of four monthly injections of poly-l-lactic acid (Sculptra). Note the decrease in both the superior pole "step-off" and the visibility of the ribs and intercostal spaces.

individuals. While a latissimus dorsi flap has shown success in even thin patients, this does not preclude the use of an implant and donor site morbidity must be considered in our active patient.

A less invasive modality that has been described is autologous fat injections into the superior pole (4). Potential complications of fat injections include development of a lipocele, fat necrosis, palpable nodules, and radiographic calcifications. While few doubt the efficacy of autologous fat injections, there remains concern that these known complications may interfere with the detection of recurrent or residual disease in a patient with a history of breast malignancy (5). Some argue that these concerns have been overemphasized and postoperative mammographic changes seen after fat injections are similar to those seen after other breast procedures (6). Regardless, this technique may be limited in an extremely thin individual, like our patient, who lacks adequate donor fat.

We initially chose to place AlloDerm into the area to add thickness to the soft tissue and camouflage the defects. We layered extra thick AlloDerm in the area after performing an open capsulotomy. This technique has been described for atrophic capsules but not specifically for soft tissue augmentation of the chest. Although the initial result was encouraging, the AlloDerm ultimately resorbed early in the postoperative period, and the defect recurred.

As we have been using Sculptra for HIV-associated lipoatrophy of the face and are satisfied with the results, we extrapolated that soft tissue correction of the chest wall in this patient would also be successful. This nonsurgical alternative is advantageous in our patient who had already undergone multiple surgical procedures and did not desire additional surgical intervention. Repeated surgical interventions may lead to a worse cosmetic outcome by creating additional scarring in an already compromised site. This non-invasive

technique with Sculptra was a good option in this particular patient when compared with repeat AlloDerm grafting, implant exchange, or a myocutaneous flap.

Sculptra is an FDA-approved treatment for restoration and/or correction of the signs of facial fat loss in people with HIV. The physiologic mechanism by which Sculptra corrects facial depressions should be the same in other non-facial soft tissue deformities. After Sculptra is injected, the fluid containing the poly-l-lactic acid crystals is dispersed within the depressed area, resulting in a temporary correction of the deformity. After a few days, water absorption and edema reduction bring the depressed area back to its pre-injection baseline. Over the next several weeks, fibroblasts are stimulated to form collagen around the individual poly-l-lactic acid crystals. This provides a progressive improvement in dermal thickness, effectively providing a correction that can last for 2 years (7). This volume correction is the result of the patients' own collagen and not a result of foreign material.

Although Sculptra provides an excellent method to correct soft tissue deformities, the cost can be significant depending on the amount of material and number of treatments required. Therefore treatment cost cannot be ignored when thinking of Sculptra treatments as a temporary solution. However, if this method can offer successful results without the cost of a surgical procedure and the required recovery, patients might find this "temporary" treatment desirable.

Some reported complications of Sculptra use include bruising, edema, discomfort, erythema, subcutaneous nodules, and hematoma. Many of these complications are the result of injection technique and can be avoided with proper instruction and experience of the injector. Overcorrection can be avoided by waiting the appropriate duration between treatments to assess the need for additional treatments. Palpable superficial nodules can be avoided by following the manufacturer's guidelines regarding proper dilution and avoiding intradermal injection (8,9).

Our experience with this product has enabled us to adapt our injection technique to the patient and the defect. In this situation, we reconstituted the Sculptra with more diluent than we do in the correction of facial lipoatrophy. The material was diluted with 4 mL of water and 2 mL of 1% lidocaine. We injected this in a macrodroplet technique. A 0.6 mL depot vol-

ume was placed in the intercostal space superficial to the intercostal muscles and manual massage was used to spread the solution medially and laterally. This minimized the number of needle sticks, thereby minimizing potential for pneumothorax.

Although there are potential complications associated with the use of Sculptra, we have found this product to be extremely safe and effective. The potential for complications can be minimized through proper injection technique and knowledge of anatomy of the treated area. The risks of this nonsurgical treatment must be weighed against the potential complications of repeated surgical interventions.

CONCLUSION

Sculptra has been used in the correction of HIV-associated facial lipoatrophy. It is being increasingly used for facial volumization in the non-HIV patient. We have presented a successful case of its use in the correction of a persistent chest wall defect after implant reconstruction in an extremely thin woman. While other methods have been described, Sculptra provides a nonsurgical treatment alternative. It can be as efficacious as fat injections in improving contour irregularities; however, Sculptra offers an easily-available, predictable product without potential donor site morbidity. While we need to evaluate the effect, if any, this treatment has on future mammography, we would reason that this technique should result in less radiographic microcalcifications than autologous fat injections and would be more easily interpreted by an experienced radiologist.

In a patient who has undergone repeated surgical procedures, all with the same objective of regaining normal breast appearance, we propose this innovative, less invasive approach. We feel that this treatment can be applied to other soft tissue deformities throughout the body and may be considered as a primary repair technique. We feel that this may be a useful, minimally invasive, alternative for the correction of large biopsy or partial mastectomy defects of the breast.

REFERENCES

1. Stokes RB. Breast augmentation in thin women: patient satisfaction with saline-filled implants. *Aesthetic Plast Surg* 2004;28:153-7.
2. Baxter RA. Intracapsular allogenic dermal grafts for breast implant related problems. *Plast Reconstr Surg* 2003;112:1692-6.

3. Lam SM, Azizzadeh B, Gravier M. Injectable poly-L-lactic acid (Sculptra): technical consideration soft-tissue contouring. *Plast Reconstr Surg* 2006;118(Suppl. 3):55S–63S.
4. Delay E, Delaporte T, Sinna R, *et al.* Breast implant alterations. *Ann Chir Plast Esthet* 2005;582:652–72.
5. Spear SL, Wilson HB, Lockwood MD. Fat injection to correct contour deformities in the reconstructed breast. *Plast Reconstr Surg* 2005;116:1300–5.
6. Coleman SR, Saboeiro AP. Fat grafting to the breast revisited: safety and emphasis. *Plast Reconstr Surg* 2007;119:775–85.
7. Broder KW, Cohen SR. An overview of permanent and semi-permanent fillers. *Plast Reconstr Surg* 2006;118(Suppl. 3):7S–14S.
8. Bauer U, Vlegaar D. Response to “New-fill injections may induce late-onset foreign body granulomatous reaction”. *Plast Reconstr Surg* 2006;118:265.
9. Andre P, *et al.* Adverse reactions to dermal fillers: a review of European experiences. *J Cosmet Laser Ther* 2005;7:171–6.